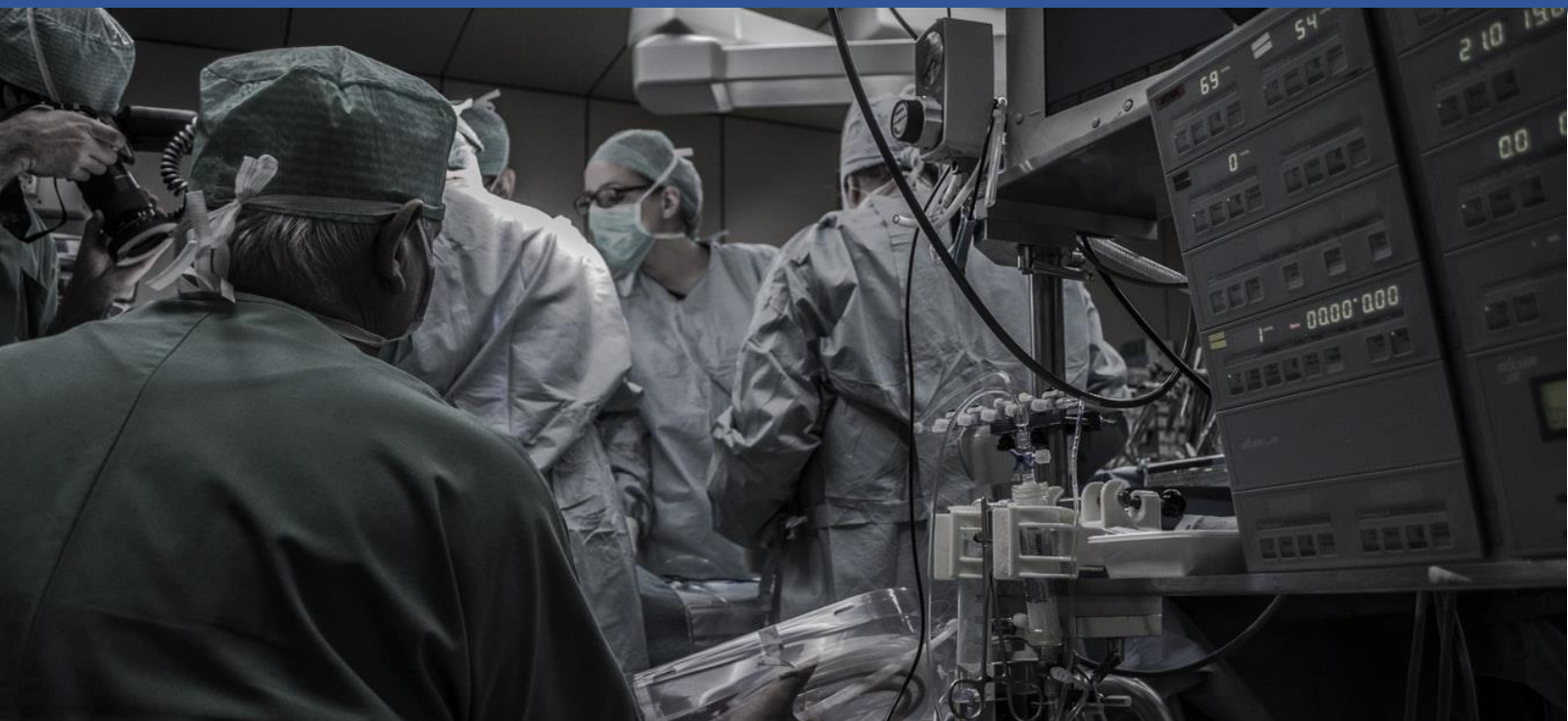

## Contents

**Cardiac Remodeling.....1**

**Case of Two Appendixes? .....3**

**Focus on Pharm.....5**

This is a new quarterly research newsletter featuring articles written by faculty of the Division of Physician Assistant Practice at Ohio University.



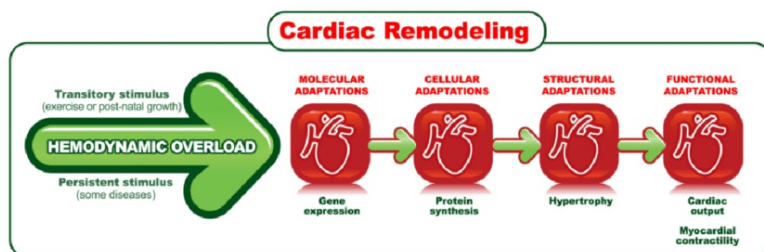
**OHIO**  
UNIVERSITY

COLLEGE OF HEALTH SCIENCES AND PROFESSIONS  
DIVISION OF PHYSICIAN ASSISTANT PRACTICE

Please contact Jeff Vasiloff, MD, MPH at [vasiloff@ohio.edu](mailto:vasiloff@ohio.edu) with any questions regarding this issue. If you would like to subscribe to receive this email in the future, please contact [nbell@ohio.edu](mailto:nbell@ohio.edu).

## Cardiac Remodeling

by Jeff Vasiloff, MD, MPH



Remodeling is so important in the pathogenesis of so many diseases. What is it? First, “remodeling” is a poorly-chosen word. This is because the good-sounding word remodeling—in medicine and pathophysiology—is always maladaptive.

Pathophysiological remodeling includes “rebuilding,” but the remodeling of body tissues often only “helps” in the short term. That is, remodeling STARTS as an adaptive process, but in the long-term, this “well-intentioned” adaptation always becomes maladaptive.

# Patho Plus for PA's

Consider the heart. After a myocardial infarction some patients develop heart failure immediately, while a large majority do not. Due to maladaptive remodeling though, heart failure ensues in up to 25% of these patients in the next ten years.

In patients who develop heart failure within five years after a myocardial infarction, while the heart failure may not have been clinically present after the infarction, the remodeling process began with the acute infarct. In other words, the remodeling process was "set into motion" at the time of the infarction.

Thus, cardiac remodeling does not happen "for no reason"; rather, it is triggered by a pathological event or process that affects the heart. While the most common triggering pathophysiologic factor is death of myocardial tissue due to infarct, there are several other triggers that set the remodeling process in action. These include: a) ventricular pressure overload (hypertension, aortic stenosis); b) ventricular volume overload (aortic regurgitation, mitral regurgitation); c) viral myocarditis or autoimmune attack of the myocardium; d) genetic mutations of cytoskeletal and other myocardial proteins; e) alcohol and chemotherapeutic agents that damage the heart; and f) infiltration of the heart with sarcoidosis or amyloidosis or excess accumulations of iron;

When the process of remodeling takes root, there does not appear to be a homeostatic script to keep the process in check. For example, in aortic stenosis, a little bit of left ventricular hypertrophy can be initially adaptive, but progressive hypertrophy ultimately leads to impaired ventricular contraction. It is useful to think of unchecked or untreated remodeling as a runaway train headed for disaster.

This is why a goal of post-infarct therapy is to PREVENT or minimize remodeling. For example, all of the following treatment strategies act to prevent or minimize remodeling: a) blood pressure control; b) lowering of LDL cholesterol; c) adrenergic blockade with beta blockers; d) renin-angiotensin-aldosterone blockade with ACE inhibitors or angiotensin I receptor blockers (ARBs); e) coagulation system inhibition with, for example, cyclooxygenase I inhibitors (aspirin) and platelet P2Y<sub>12</sub> inhibitors (for example, clopidogrel); f) and anti-ischemic therapy with nitrates.

While the maladaptive effects of cardiac remodeling can affect the entire heart and cardiovascular system, the underlying deleterious remodeling occurs at the molecular and cellular levels. That is, remodeling results from changes in gene expression and protein synthesis, which ultimately give rise to cellular changes such as fibrosis, hypertrophy, and necrosis.

The pathway of remodeling following an initial insult to the heart involves the secretion of sky high levels of mediators and hormones. These mediators and hormones, in turn, change the structure and function of the heart.

Some of these mediators and hormones include: a) renin; b) angiotensin I; c) angiotensin II; d) aldosterone; e) epinephrine; f) norepinephrine; g) arginine vasopressin (same as anti-diuretic hormone); h) atrial natriuretic peptide (ANP); and i) endothelin-1, among others.

It is the high levels of these mediators and hormones in both the blood and cardiac tissue that cause the maladaptive lesions and changes of remodeling.

The consequences of remodeling include such changes as: a) myocardial (or myocyte) death; b) myocyte enlargement (hypertrophy); c) deposition

# Patho Plus for PA's

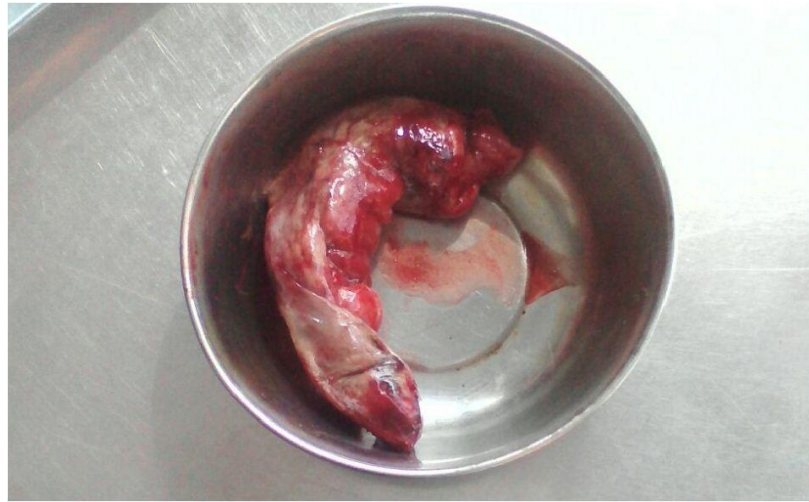of fibrous tissue; d) activation of the coagulation system; and e) chamber enlargement.

These changes, in turn, can lead to: a) increased systolic (chamber) wall tension and stress; b) increased demand for oxygen; c) impaired shortening of myocardial cells during contraction; d) increased diastolic (chamber) wall tension and stress; e) decreased perfusion of the subendocardial area of the myocardium; f) impairment of "tight coupling" of myocardial depolarization and myocardial contraction; g) mitral regurgitation due to LV enlargement with separation of papillary muscles; and h) ventricular arrhythmias, including ventricular fibrillation;

Again, the many treatment modalities in patients with various heart diseases are used to attempt to prevent sequelae of maladaptive cardiac remodeling.

## Case of Two Appendixes?

by Shanna Raphael, PA-S and Jeff Vasiloff, MD, MPH



### Report of a Case:

A 25 year old woman was in her usual state of health until she developed the sudden onset of severe crampy pain in the suprapubic area. This was accompanied by nausea and diarrhea without hematochezia.

She denied dysuria or frequency, and a routine gynecologic examination 3 weeks prior was unremarkable. There was no history of irritable bowel or inflammatory bowel disease. She had appendicitis 6 years ago treated with laparoscopic appendectomy.

Other past medical history was unremarkable. She is a single PA student. No history of smoking or drug use. She is a social drinker. Family history was positive for diverticulitis. Review of systems was negative except for anorexia, nausea, and abdominal pain.

Temperature was 98.3°F; pulse was 93 per minute and regular; respirations were 14 per minute; blood pressure was 147/86 mmHg; O<sub>2</sub> saturation was 98%.

She appeared uncomfortable due to abdominal pain. HEENT exam was normal. Cardiopulmonary exam was normal. Abdomen was nondistended. There was moderate tenderness in the suprapubic

# Patho Plus for PA's

area but without peritoneal signs. There was no CVAT and the remainder of the examination was normal.

WBC was  $11,330 \text{ mm}^3$  with 73% neutrophils, 19% lymphs, 5% monos, and 2% basos. Hemoglobin was 13.8 g/dL; hematocrit was 42%.

Complete metabolic panel was normal except for a glucose of 114 mg/dL and bicarbonate of 20 meq/L. Anion gap was 21. Lipase was normal and beta-hCG was negative. Urinalysis revealed no white blood cells, but 11 red blood cells per HPF. Leukocyte esterase was negative, and bacteria were seen only rarely.

During observation in the emergency department, she did not have any further episodes of diarrhea, but the abdominal pain persisted in spite of IV analgesia. Further, she remarked that the pain was reminiscent of her acute appendicitis 6 years previously.

A contrast CT of the abdomen and pelvis revealed surgical clips in the right lower quadrant, presumably from prior appendectomy. In addition, although the terminal ileum was not dilated, the small bowel proximal to it was distended to 2.7cm, consistent with low-grade partial small bowel obstruction.

She was admitted to the surgery service where she received IV hydration and additional pain control. The following morning she felt some better, but abdominal x-rays revealed some prominent loops of small bowel with air-fluid levels--consistent with the CT findings the day before.

Small bowel follow through with water-soluble contrast revealed the appearance of contrast within the colon in 45 minutes confirming the absence of complete obstruction.

It was decided to perform diagnostic laparoscopy, but the patient requested postponement due to an upcoming midterm. She was counseled on the

risks and instructed to call and return to the ED if symptoms worsened.

Over the next week she was able to attend school despite steady abdominal pain, which now was most intense in the right lower quadrant. She also had constipation. Her oral intake was reduced because of occasional nausea and vomiting.

Nine days after discharge she was readmitted for diagnostic laparoscopy. Preoperatively, her abdomen was nondistended, but diffuse tenderness to palpation was present. There were no peritoneal signs and WBC was  $7,730 \text{ mm}^3$ .

Full diagnostic laparoscopy of the abdomen and pelvis revealed a normal appearing small bowel at its surface. Then it was run--"hand over hand"--laparoscopically with the robot. The bowel in the right lower quadrant was saved for last.

Inspection of the right lower quadrant revealed the cecum to be rotated into the colic gutter. Also, there were staples along the peritoneum overlying the iliac vessels--secondary to prior appendectomy.

In addition, the area was bound down by dense adhesions, which were lysed. This allowed the straightening out of the cecum and terminal ileum. It could then be seen that there was a 15-20 cm fecalized segment of small bowel leading to the ileocecal valve and cecum. There was also the presence of an unknown structure that contained staple lines.

Further dissection revealed that the unknown structure was appendix. That is, about half of the appendix was found remaining. Thus, in the appendectomy 6 years previously, only part of the appendix had been removed.

The rest of the appendix--down to its attachment to cecum--was resected. The remnant was removed through the port site.

# Patho Plus for PA's

Examination of the specimen revealed a large remnant of the appendix, which, surprisingly, did not appear inflamed. The appendiceal remnant, however, was missing the tip, which is consistent with prior partial resection, leaving behind most of the body of the appendix. Resection of the remnant appendix and adhesions relieved the constriction of the distal ileum.

## Discussion:

Bowel obstruction refers to the blockage of transit through the lumen of the bowel. Blockage or obstruction can be complete or partial. Common causes of bowel obstruction include physical or mechanical blockage or "functional" blockage, the latter usually due to bowel hypomotility—that is, paralytic ileus.

The leading cause of mechanical obstruction of the small bowel is a "pinching" or constriction of the bowel lumen due to entrapment by fibrous adhesions from previous surgeries or inflammatory conditions. Entrapment within hernias (inguinal, incisional, ventral, for example) is the second leading cause.

Less common causes include: a) intussusception (telescoping of one segment of bowel within another); b) volvulus (twisting constriction of the bowel); and c) intraluminal blockages, such as caused by a small bowel tumor or impacted gallstone (gallstone ileus);

Appendectomy is one of the most common surgical procedures. Postoperative complications include wound infection, bleeding, intrabdominal abscess, small bowel obstruction, and stump appendicitis.

Most cases of small bowel obstruction following appendectomy are caused by adhesions. The formation of these fibrous bands is to be expected following intraperitoneal surgery or secondary to inflammation. On some occasions, these bands

form orifices or "passageways" into which small bowel can enter and become entrapped.

This is what appears to have happened in this case, with the additional feature of the presence of a remnant of the appendix also bound down with adhesions.

Leaving an appendiceal remnant (also called a "stump") has been reported to be associated with bowel obstruction. In 2004, Gordon et. al. reported a 36 year old woman who developed partial small bowel obstruction 10 days after laparoscopic appendectomy.<sup>1</sup> At operation, there was no stump appendicitis, but, rather, the tip of the stump was affixed to the mesentery of the terminal ileum, which lead to the entrapment of the terminal ileum.<sup>1</sup>

More common than bowel obstruction in the presence of a remnant appendix, is acute inflammation of the remnant—so called "stump appendicitis."

In 2011, Roberts et. al. reviewed all reported cases of stump appendicitis.<sup>2</sup> There were 48 cases, including 3 of their own patients. Stump appendicitis presents like acute appendicitis, but, of course, in a patient who has already undergone ("partial") appendectomy.

Thus, it is important that PA's remember that in a patient presenting with acute right lower quadrant pain and a history of prior appendectomy, stump appendicitis or even stump-related small bowel obstruction are diagnostic possibilities.

## References:

1. Gordon R, Bamehriz F, and Birch DW. Residual appendix producing small-bowel obstruction after laparoscopic appendectomy. *Can J Surg*. 2004; 47(3): 217-218.
2. Roberts KE, Starker LF, Duffy AJ, Bell RL, and Bokhari J. Stump appendicitis: a surgeon's dilemma. *J Soc Laparendosc Surg*. 2011; 15(3): 373-378.

# Patho Plus for PA's

## The Skinny on Weight Loss Drugs in Ohio

by Kristin Lugo, Pharm.D.



From 2000 to 2018, Ohio has seen a 14% increase in obese adults.<sup>1</sup> Currently, Ohio ranks number 17 in the United States for adult obesity.<sup>1</sup> It is well known that obesity is a risk factor for type 2 diabetes, cardiovascular disease, and hypertension. Addressing weight is a necessary part of improving overall health for patients. Implementing a healthy diet and increasing physical activity are essential to long-term weight management. Some patients may benefit from the addition of weight loss drugs to jump-start the process or help them stay on track with lifestyle changes. There are both controlled and non-controlled medications FDA approved for weight loss. Unique rules in Ohio address the prescribing of controlled substances for weight loss. While these rules may be cause for pause, understanding them gives the provider an added tool when helping patients lose weight.

Although there are four FDA approved medications for short-term management of weight reduction, phentermine (Adipex-P®, Lomaira®) is the most commonly prescribed.<sup>2,3,4</sup> To prescribe this drug in Ohio, the prescriber must be a physician. The physician must first review the patient's medical

record and assess what attempts have been made to lose weight.<sup>5</sup> If past attempts have been unsuccessful and the physician is considering prescribing phentermine, several steps must take place. The physician begins by completing a history and physical, calculating the patient's BMI, and assessing contraindications to the use of phentermine.<sup>5</sup> The patient's BMI must be 30 or higher (27 or higher with comorbidities) to initiate treatment.<sup>5</sup> If there are no contraindications and the BMI requirement is met, the physician may prescribe phentermine in conjunction with diet and exercise.

Prescriptions for phentermine may not exceed 30 days and total treatment time may not exceed 12 weeks.<sup>5</sup> The physician must see the patient in person at least every 30 days during treatment with phentermine to assess progress.<sup>5</sup> At the completion of 12 weeks of treatment, the patient may not start another short-term weight loss medication for 6 months.<sup>5</sup> However, where appropriate, the physician may switch the patient to one of the long-term controlled substances for weight loss.

Qsymia® (phentermine/topiramate) and Belviq® (lorcaserin) are FDA approved controlled substances for the long-term management of weight loss.<sup>6,7</sup> Beginning treatment with these medications also begins with an in-person visit with the physician who will complete a history and physical, calculate the patient's BMI, and assess contraindications to the use of either medication.<sup>8</sup> The physician will see the patient, face-to-face, every 30 days for two additional follow-up visits.<sup>8</sup> After the first three visits, the physician can choose to write a six month prescription for the patient and/or have the patient followed by their physician assistant.<sup>8</sup> Physician assistants may not change the prescribed medication to a different product.<sup>8</sup>

As with any controlled substance in Ohio, OARRS must be monitored.<sup>5,8</sup> Patients with a history of

# Patho Plus for PA's

drug abuse or those who have provided false information regarding controlled substance use should not receive controlled substances for weight loss.<sup>5,8</sup> Signs of abuse or diversion while taking controlled substances for weight loss should be investigated and discontinuation of therapy may be warranted.<sup>5,8</sup>

## References:

1. State Briefs. *The State of Obesity*. <https://www.stateofobesity.org/states/oh/>. Accessed September 16, 2019.
2. ADIPEX. <https://www.adipex.com/>. Accessed September 16, 2019.
3. LOMAIRA. [https://lomaira.com/?gclid=EAlaIqObChMI0K3wvu\\_V5AIVycDACH03cwAXEAAAYASAAEgKpM\\_D\\_BwE](https://lomaira.com/?gclid=EAlaIqObChMI0K3wvu_V5AIVycDACH03cwAXEAAAYASAAEgKpM_D_BwE). Accessed September 16, 2019.
4. Hendricks EJ. Off-label drugs for weight management. *Diabetes Metab Syndr Obes*. 2017;10:223–234. Published 2017 Jun 10. doi:10.2147/DMSO.S95299
5. Lawriter - OAC - 4731-11-04 Controlled substances: Utilization of short term anorexiant for weight reduction. <http://codes.ohio.gov/oac/4731-11-04>. Accessed September 16, 2019.
6. BELVIQ and BELVIQ XR HCP Home Page. <https://www.belviq.com/hcp>. Accessed September 16, 2019.
7. Prescription Weight Loss with Qsymia® (Phentermine and Topiramate extended-release) Capsules CIV. <https://qsymia.com/hcp/>. Accessed September 16, 2019.
8. Lawriter - OAC - 4731-11-04.1 Controlled substances: utilization for chronic weight management. <http://codes.ohio.gov/oac/4731-11-04.1v1>. Accessed September 16, 2019.